

STS National Database:

ACSD Monthly Webinar

March 6, 2024

Agenda

Welcome and Introductions

STS Updates

Cerebrovascular Disease

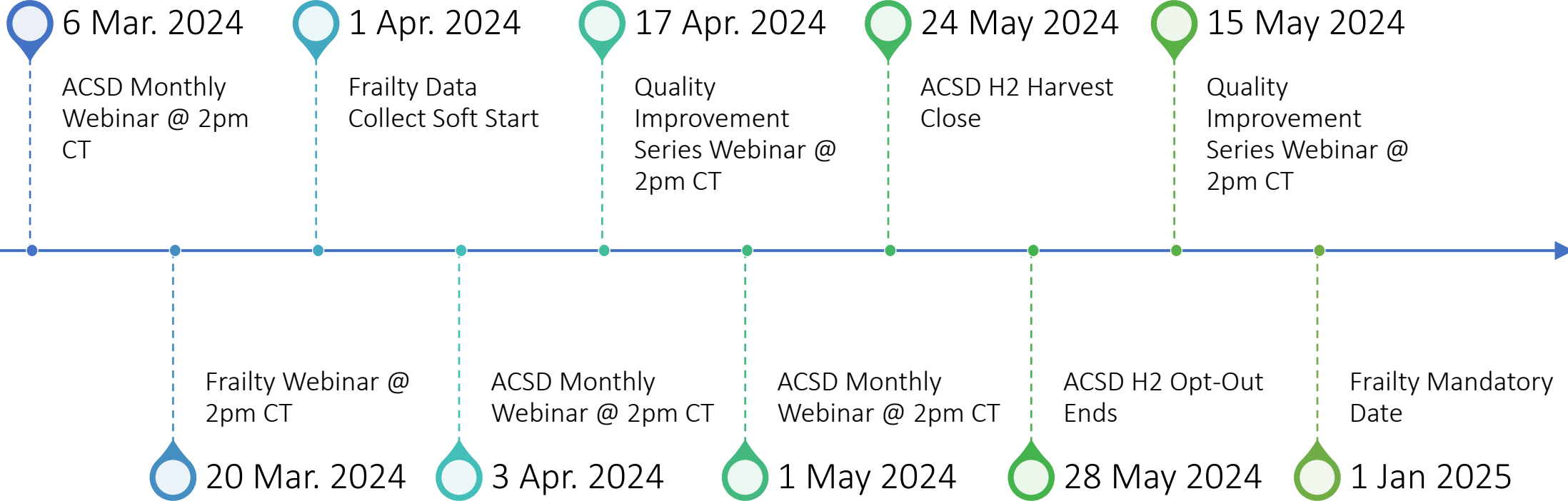
STS Updates

March Training Manual
Posted

H1 Closed on February 23,
2024

Frailty Data Collection
Starting April 1

Important Dates



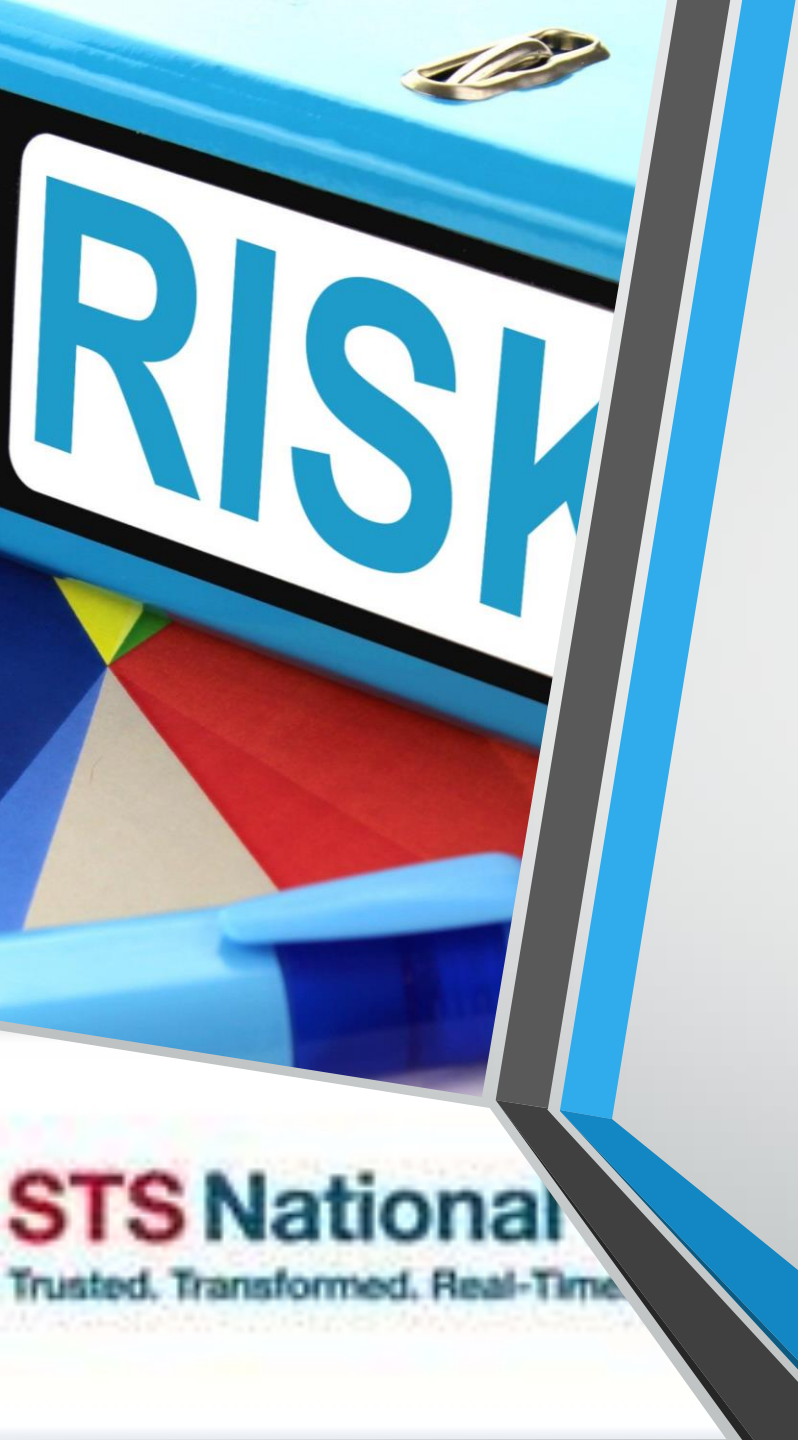Harvest 2024 Dates

2024 Harvest

Term	Harvest Submission Window Close	Opt-Out Date	Includes Procedures Performed Through:	Report Posting	Comments
Harvest 1	2/23/2024	02/27/2024	12/31/2023	Spring 2024	Star Rating
Harvest 2	5/24/2024	05/28/2024	3/31/2024	Summer 2024	
Harvest 3	8/23/2024	8/27/2024	6/30/2024	Fall 2024	Star Rating
Harvest 4	11/22/2024	11/26/2024	9/30/2024	Winter 2024	



Data Submission Open is continuous for all harvest terms. Submission Close occurs at 11:59 p.m. Eastern on the date listed.



Cerebrovascular Disease

Risk Factors

CVD, CVA, CVA When, CVD TIA,
CVD Carotid Stenosis R & L, and
CVD Prior Carotid Surgery are in the
Risk Model

All of the above were 2023 Audit
fields

Cerebrovascular Disease Seq 525

Indicate whether the patient has a current or previous history of any of the following:

- Stroke: Stroke is an acute episode of focal or global neurological dysfunction caused by brain, spinal cord, or retinal vascular injury as a result of hemorrhage or infarction, where the neurological dysfunction lasts for greater than 24 hours.
- TIA: is defined as a transient episode of focal neurological dysfunction caused by brain, spinal cord, or retinal ischemia, without acute infarction, where the neurological dysfunction resolves within 24 hours.
- Noninvasive or invasive arterial imaging test **demonstrating $\geq 50\%$** stenosis of any of the major extracranial or intracranial vessels to the brain.
- Vertebral artery disease and/or internal carotid disease and/or intracranial disease **=> 50% stenosis**, code Yes to Cerebrovascular Disease. **External carotid disease is excluded.**
- Previous cervical or cerebral artery revascularization surgery or percutaneous intervention
- Brain/cerebral aneurysm
- Occlusion of vertebral artery, internal carotid artery, and intracranial due to dissection



Question #1

Would vascular dementia be coded as
yes to CV disease?

A. Yes

B. No



Answer #1

Would vascular dementia be coded as yes to CV disease?

A. Yes

B. No

You must have one of the qualifiers that we pointed out in the previous slide to code CVD.



Question #2

Pt has history of subdural
hematoma. Would I code Yes to
CVD?

A. Yes

B. No



Answer #2

Pt has history of subdural hematoma.
Would I code Yes to CVD?

- A. Yes
- B. No

Subdural hematoma or AVM is not coded as cerebral vascular disease per the Training Manual.



Question #3

During Pre-op work-up, duplex US revealed occluded right vertebral artery. Can I code this as Cerebrovascular Disease?

- A. Yes
- B. No



Answer #3

During Pre-op work-up, duplex US revealed occluded right vertebral artery. Can I code this as Cerebrovascular Disease?

A. Yes

B. No

Vertebral artery disease and/or internal carotid disease and/or intracranial disease => 50% stenosis, code Yes to Cerebrovascular Disease seq 525. External carotid disease is excluded.

Code No to all child fields under 525.



Question #4

My patient has a 60% stenosis in the carotid bulb. Can I code CVD?

A. Yes

B. No



Answer #4

My patient has a 60% stenosis in the carotid bulb. Can I code CVD?

- A. Yes
- B. No

Update April 2022 disease at the carotid bifurcation can be captured.

The carotid sinus, also known as the carotid bulb, is a neurovascular structure that appears at the bifurcation of the common carotid artery, and the beginning of the internal carotid artery.



Question #5

CT head was done 2 days post-op on a CABG patient. The CT report showed a chronic lacunar infarction. Can I code CVD with prior CVA?

A. Yes

B. No



Answer #5

CT head was done 2 days post-op on a CABG patient. The CT report showed a chronic lacunar infarction. Can I code CVD with prior CVA?

A. Yes

B. No

A CT scan following surgery with evidence of old infarct or chronic infarct should be coded yes.



Question #6

My patient has a history of a subarachnoid hemorrhage. Do I code this as CVD?

- A. Yes
- B. No



Answer #6

My patient has a history of a subarachnoid hemorrhage. Do I code this as CVD?

A. Yes

B. No

Not all subarachnoid hemorrhages will create a stroke. There must be some form of deficit (symptoms lasting > 24 hr.) documented in the chart to code SAH as a CVA



Question #7

Aortic dissection patient – Pre-op CT shows innominate and left carotid were dissected and occluded. Can I code carotid stenosis in this patient?

- A. Yes
- B. No



Answer #7

Aortic dissection patient – Pre-op CT shows innominate and left carotid were dissected and occluded. Can I code carotid stenosis in this patient?

A. Yes

B. No

If dissection occluded the artery, then code as 100%,

In a dissection because the blood flow is null it acts like an occlusion.



Question #8

Patient had a CABG on 12/23. Bilateral US Carotid Doppler completed on 12/29 showed 50-69% stenosis of the LEFT ICA. Can this post-op study be used to code SEQ# 525?

- A. Yes
- B. No



Answer #8

Patient had a CABG on 12/23. Bilateral US Carotid Doppler completed on 12/29 showed 50-69% stenosis of the LEFT ICA. Can this post-op study be used to code SEQ# 525?

A. Yes

B. No

*The timeframe for carotid stenosis is to code the study closest **and prior to OR Entry**, done within 1 year of OR date.*



Question #9

Can I use the ratio to count this as carotid stenosis?

Velocities suggest 1-49% stenosis of the right internal carotid artery.

ICA/CCA ratio of 2.06 is suggestive of 50-69% stenosis of the right internal carotid artery.

A. Yes

B. No



Answer #9

Can I use the ratio to count this as carotid stenosis?

Velocities suggest 1-49% stenosis of the right internal carotid artery.

ICA/CCA ratio of 2.06 is suggestive of 50-69% stenosis of the right internal carotid artery.

A. Yes

B. No

*Update Sept 2021 – If Carotid Ultrasound results are reported in both Velocity and Ratio measurements on the study closest to entry into OR, **code the measurement that has the highest degree of stenosis.***



Question #10

Carotid Ultrasound prior to Left CEA:

1. The luminal diameter of the proximal right internal carotid artery is narrowed by approximately 70%
2. The of the lumen of the proximal left internal carotid artery is narrowed by approximately 81%.

The patient has a Left CEA on 1/17 prior to a CABG on 1/19. Should Seq# 545 be coded as Right or Both?

A. Right

B. Both



Answer #10

Carotid Ultrasound prior to Left CEA:

1. The luminal diameter of the proximal right internal carotid artery is narrowed by approximately 70%
2. The of the lumen of the proximal left internal carotid artery is narrowed by approximately 81%.

The patient has a Left CEA on 1/17 prior to a CABG on 1/19. Should Seq# 545 be coded as Right or Both?

A. Right

B. Both

Right since the left stenosis has been corrected by the CEA. Code prior carotid surgery for the left.

We want to capture what the carotid stenosis was prior the patient is entering the OR for surgery.



Question #11

My patient has a history of internal carotid artery aneurysm coiling. Do I capture this as previous carotid artery surgery?

- A. Yes
- B. No



Answer #11

My patient has a history of internal carotid artery aneurysm coiling. Do I capture this as previous carotid artery surgery?

- A. Yes
- B. No

Seq 560 CVD Prior Carotid Surgery also includes internal carotid artery aneurysm coils and a history of carotid angioplasty.



Question #12

Past Surgical History:
CAROTID ARTERY - SUBCLAVIAN ARTERY
BYPASS GRAFT for Subclavian artery stenosis.
Is this coded as CVD or PVD?

- A. CVD Seq 525
- B. PVD Seq 505



Answer #12

Past Surgical History:
CAROTID ARTERY - SUBCLAVIAN ARTERY
BYPASS GRAFT for Subclavian artery stenosis.

Is this coded as CVD or PVD?

A. CVD Seq 525

B. PVD Seq 505

The bypass was done for subclavian stenosis which is coded as PVD in seq 505.



Question #13

Patient has a history of prior left vertebral artery occlusion with distal reconstruction. Can I code prior carotid artery surgery?

- A. Yes
- B. No



Question #13

Patient has a history of prior left vertebral artery occlusion with distal reconstruction. Can I code prior carotid artery surgery?

- A. Yes
- B. No

Update Feb 2022 - Patient with prior left vertebral occlusions with distal reconstruction can be coded in SEQ 525 (CVD). Do not code in SEQ 560 Prior Carotid Surgery.



Resources

- STS National Database Webpage
- STSDB_Helpdesk@sts.org (Uploader, DQR, Missing Variable, Dashboard, Password and Login)
- STS National Database Feedback Form
- Resource Documents
 - Contact Information
 - Webinar Information
 - FAQ Document
 - Go-Live Checklist
 - Tiered-level Support Document
 - *Training Videos*
 - *Link to IQVIA*
 - ckrohn@sts.org



Open Discussion

Please use the
raise-hand
function.

Please use the
Q&A Function.

We will answer as
many questions as
possible.

We encourage
your feedback and
want to hear from
you!